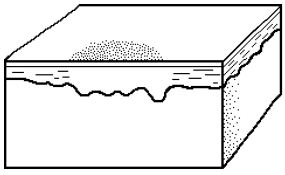
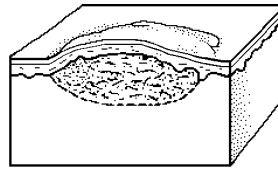


Macule



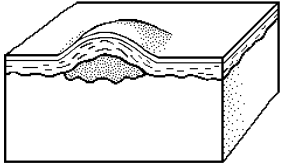
A flat, nonpalpable discoloration of the skin. It may have a distinct outline or fade into the surrounding skin. Macules can be any color. Examples: Tattoo, freckle, drug eruption.

Wheal



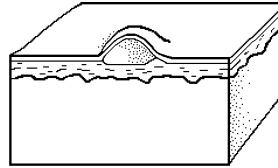
A transient elevation of the skin that may have a central pallor. It is caused by edema of the dermis and surrounding capillary dilation. Examples: Urticaria (hives) angioedema (swelling).

Papule



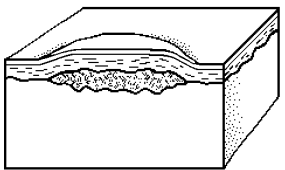
A small elevated palpable lesion under .5 cm in diameter. Examples: skin tag, Kaposi's sarcoma (A malignant neoplasm that begins as a soft brownish or purple papule on the feet and slowly spreads and enlarges to a nodule).

Vesicle



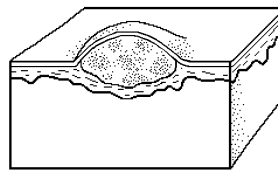
An elevation less than .5 cm in diameter that contains a fluid. Examples: Varicella (chicken pox), herpes zoster (shingles).

Plaque



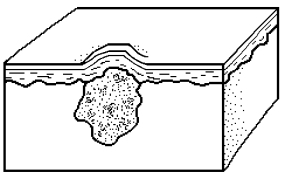
A solid, elevated plateau that is greater in its diameter than in its depth. Often formed by the confluence of papules. Examples: Psoriasis, (scaling plaques), eczema (inflammatory disease), lupus (chronic cutaneous).

Bulla



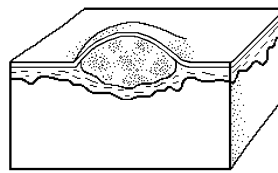
An elevation greater than .5 cm that contains fluid. Example: blister.

Nodule



An elevated solid lesion greater than .5 cm in diameter. A large nodule is referred to as a tumor. Examples: Xanthoma (yellowish plaque or nodule), gout (painful swelling of a joint).

Pustule



A small elevation that contains purulent fluid. Examples: Acne, folliculitis.